Zhang *et al. BMC Pediatrics* (2025) 25:63
https://doi.org/10.1186/s12887-025-05436-8

BMC Pediatrics

RESEARCH Open Access

Severe central nervous system injury in 9 children with COVID-19

Peipei Zhang[1†], Meiyun Xin[1†], Yingge Bai[2], Xueyun Ren[1] and Na Li[1,3*]

Abstract

Purpose To investigate the clinical features and prognosis of severe central nervous system (CNS) injury in children caused by coronavirus disease 2019 (COVID-19).

Method We retrospectively studied confirmed pediatric cases of COVID-19 complicated with CNS injury.

Results Nine patients diagnosed with COVID-19 complicated with severe CNS injury were admitted to the pediatric intensive care unit of the Affiliated Hospital of Jining University from December 1, 2022 to January 12, 2023. Of the nine patients, seven were male (77.78%). Five children were aged ≥ 10 years, and the others were 1–2 years old. All children had fever, eight had convulsions, seven had progressed to multiple organ failure, and all suffered varying degrees of coma. Most of the children had elevated interleukin-6 (100%), lactic acid (100%), alanine transaminase (87.5%), aspartate transaminase (87.5%), creatine kinase MB (87.5%), and lactate dehydrogenase (85.7%) levels. Four children had cerebrospinal fluid proteinnacell separation. The cranial imaging results of five children were abnormal. One child had lost his vital signs when admitted to hospital, and the remaining eight received hormonal shock, human immunoglobulin transfusion, antinainfection, cranial pressure reduction, and tracheal intubation, among others, during hospitalization. Ultimately, eight children died, and the remaining child has serious neurological sequelae and is undergoing rehabilitation.

Conclusions Severe CNS injury caused by COVID-19 has an acute onset, rapid progression, high disability rate, and high fatality rate. A low cerebrospinal fluid protein level may be a protective factor for children with severe nervous system injury caused by COVID-19.

Keywords COVID-19, Severe central nervous system injury, Children

Introduction

The novel coronavirus disease 2019 (COVID-19) pandemic has brought great clinical challenges worldwide. Since the beginning of the pandemic, neurologic manifestations in patients with COVID-19 have been extensively described [1, 2].

More serious neurological disorders, such as encephalitis (inflammation of the brain) and encephalopathy (a brain disease characterized by altered consciousness), are rare complications of COVID-19 and are often fatal [3, 4]. For example, a study that included 3,707 children reported that only 1% developed encephalopathy [5], but

[†]Peipei Zhang and Meiyun Xin contributed equally to the paper as first authors.

*Correspondence:
Na Li
lnygz7050@163.com
[1]Department of Pediatrics, Affiliated Hospital of Jining Medical University, Jining 272007, Shandong, China
[2]Surrey College, Dongbei University of Finance and Economics, Dalian 116025, Liaoning, China
[3]Postdoctoral Mobile Station of Shandong University of Traditional Chinese Medicine, Jinan 250355, Shandong, China

© The Author(s) 2025. **Open Access** This article is licensed under a Creative Commons Attribution-NonCommercial-NoDerivatives 4.0 International License, which permits any non-commercial use, sharing, distribution and reproduction in any medium or format, as long as you give appropriate credit to the original author(s) and the source, provide a link to the Creative Commons licence, and indicate if you modified the licensed material. You do not have permission under this licence to share adapted material derived from this article or parts of it. The images or other third party material in this article are included in the article's Creative Commons licence, unless indicated otherwise in a credit line to the material. If material is not included in the article's Creative Commons licence and your intended use is not permitted by statutory regulation or exceeds the permitted use, you will need to obtain permission directly from the copyright holder. To view a copy of this licence, visit http://creativecommons.org/licenses/by-nc-nd/4.0/.

this was associated with increased mortality [6]. Encephalitis/encephalopathy may occur via different mechanisms, including direct infection, systemic inflammation caused by cytokine storms, and autoimmunity [7].

Since the epidemic prevention policy for COVID-19 in China was lifted in December 2022, the number of cases of COVID-19 has rapidly increased. In light of the growing number of cases, familiarizing physicians with various neurological features that may be observed in these patients is extremely important. This paper reports the condition and prognoses of nine pediatric patients complicated with central nervous system (CNS) injury. Our aim is to make clinicians aware of the severity of CNS injury in children with COVID-19 and to help them identify severe cases as soon as possible.

Materials and methods

General information

From December 1, 2022 to January 12, 2023, a retrospective review was conducted of the clinical, laboratory, and magnetic resonance imaging (MRI)/computed tomography (CT) findings of nine children admitted to the pediatric intensive care unit (PICU) of the Affiliated Hospital of Jining Medical University. The children were determined to be nucleic acidnapositive for SARS-CoV-2 by oropharyngeal swabs. Central nervous system injury is a condition in which the nerve cells and bundles of the brain, diencephalon, brainstem, cerebellum, and spinal cord are damaged or function disordered, resulting in impairments in cognition, sensation, and movement [8]. Sample collection and pathogen identification were performed after admission to the hospital. The basic information of the children was recorded, including their age, sex, symptoms, underlying diseases, and vaccination records. All laboratory tests were carried out in accordance with the health standards of the People's Republic of China.

Ethics statement

The authors are accountable for all aspects of the work in ensuring that questions related to the accuracy or integrity of any part of the work are appropriately investigated and resolved. The study was conducted in accordance with the Declaration of Helsinki (as revised in 2013). This study was approved by the Ethics Committee of Affiliated Hospital of Jining Medical University. Ethical number:2022C253.All methods were carried out in accordance with relevant guidelines and regulations. Confirm that the informed consent of all subjects' legal guardians has been obtained for this study.

Data analysis

Continuous data were expressed as means and ranges, and categorical data were presented as counts and percentages.

Results

General information

From December 1, 2022 to January 12, 2023, we encountered nine pediatric cases of COVID-19 with severe CNS injury. Of the nine patients, seven were male (77.78%) and two were female (22.22%). Five children were aged ≥ 10 years, and the other four were 1–2 years old. The latter children were not vaccinated, and six children were previously healthy. One child (10 years old at the time of admission) had a history of asthma before the age of 3 years, one child was diagnosed with acute disseminated encephalomyelitis 1 year earlier, and one child with abnormal genetic test results was diagnosed with severe encephalitis 6 months earlier and treated with oral antiepileptic drugs as maintenance therapy (Table 1).

Clinical manifestations

Six patients were admitted with hypoxemia (blood oxygen saturation < 90%), and two patients (case7, case8) were admitted with 95% blood oxygen saturation after endotracheal intubation.2 patients (case 5 and case6) had hypotension, and case9 had no vital signs when admitted.All the 9 patients had fever before admission, and five had a body temperature of ≥ 40 °C and difficulty during defervescence. Eight patients developed fever and convulsions, and the remaining child developed fever and headache. Seven patients had generalized tonicnaclonic seizures, one had an unknown form of convulsions, and four had Status Epilepticus. All patients experienced varying degrees of coma. Eight patients died, and the length of hospital stay ranged from 30 min to 5 days. The only survivor has severe neurological sequelae and is currently undergoing rehabilitation. In addition to neurological symptoms, two patients developed shock, and two others developed diffuse intravascular coagulation. Three patients developed gastrointestinal bleeding, and seven progressed to multiple organ failure involving the nervous, respiratory, circulatory, digestive, and coagulation systems.

Laboratory tests and imaging examinations

One child (case 9) did not receive any tests because his vital signs (temperature, pulse, respiration, blood pressure) had disappeared upon admission. Another child (case 1) died within half a day of admission. On admission, all patients had a higher than normal proportion of neutrophils and a lower than normal proportion of lymphocytes. Most patients had a high neutrophil-to-lymphocyte ratio of > 5.0 (75%). Platelet and hemoglobin

Table 1 General information of the 9 children with CNS consequences of COVID-19

Case No.	1	2	3	4	5	6	7	8	9
General information									
Gender	M	F	M	M	M	M	M	M	F
Age	10years	1year	10years	1year	10years	10years	2years	1year	11years
Admit date	2022/12/23	2022/12/24	2022/12/24	2022/12/26	2022/12/25	2022/12/24	2022/12/25	2022/12/26	2022/12/28
Disease progression on admission	Fever for 2 days, convulsions for 6 h, coma for 3 h	Fever for 3 days, vomiting, diarrhea for 1 day, convulsion once	Fever for 1 day, convulsions for 3 h	Fever, extra sleep for 2 days, convulsions for 10 min	Fever, headache, confusion, respiratory and cardiac arrest	Fever for 11 h, convulsions for 5 h	Fever for 8 h, three convulsions	Fever for 15 h, four convulsions	Fever for 10 h, convulsion followed by coma for 8 h
Vaccination	Yes	No	Yes	No	Yes	Yes	No	No	Yes
Underlying disease	No	ADEM	Asthma	RANB-P2NM-006767.4	No	No	No	No	No
Vital signs on admission									
Temperature (℃)	36.2	36.5	35.0	36.1	36.4	37.0	38.1	36.8	36.0
Pulse(times per minute)	116	88	56	162	124	180	170	122	0
Breathing(times per minute)	12	30	20	42	0	70	30	26	0
Blood pressure(mmHg)	127/82	105/70	127/74	87/47	84/56	60/40	95/50	-	0
Degree of blood oxygen saturation(%)	86	88	68	88	80	88	95(Tracheal intubation)	95(Tracheal intubation)	0
Physical examination on admission	Coma, No light reflex in both eyes	Coma. Positive for Babinski's sign	Coma, No light reflex in both eyes	Coma, No light reflex in both eyes	Coma, No light reflex in both eyes	Coma, No light reflex in both eyes	Coma, No light reflex in both eyes	Drug sedation	Coma, dilated pupils
Brain imaging examination was abnormal	No	Yes	Yes	Yes	No	Yes	-	Yes	-
Complication									
Convulsions	Yes	Yes	Yes	Yes	No	Yes	Yes	Yes	Yes
DIC	No	No	Yes	No	No	Yes	No	No	No
Stroke	Yes	No	Yes	No	No	No	No	No	No
Gastrointestinal bleeding	No	No	Yes	No	No	Yes	Yes	No	No
Pneumonia	Yes	Yes	Yes	Yes	No	Yes	Yes	Yes	-
Therapy									
Trachea cannula	Yes	Yes	Yes	Yes	Yes	No	Yes	Yes	Yes
Anti-infective therapy	Ceftriaxone	Ceftriaxone, acyclovir	Ceftriaxone, acyclovir, meropenem	Ceftriaxone, acyclovir	Ceftriaxone, acyclovir, Linezolid, meropenem	Ceftriaxone	Cefazoxime, Meropenem	Ceftriaxone, meropenem, acyclovir, cefoperazone and sulbactam	No
Reduced craniocerebral edema	Mannitol	Mannitol	Mannitol, Furosemide	Mannitol	Mannitol, Furosemide	Mannitol, Furosemide	Mannitol	Mannitol	No

Table 1 (continued)

Case No.	1	2	3	4	5	6	7	8	9
Sedative	Midazolam	Midazolam, levetiracetam	Midazolam	Midazolam, levetiracetam	Midazolam	Midazolam, sodium valproate, phenobarbital	Midazolam	Midazolam, levetiracetam, chloral hydrate	No
Methylprednisolone	Yes	Yes	Yes	Yes	Yes	No	Yes	Yes	No
IVIG	Yes	Yes	Yes	Yes	Yes	No	Yes	Yes	No
Prognosis	Die	Die	Die	Die	Die	Die	Die	Alive	Die
Survival time	22 h 55 min	120 h 20 min	23 h 5 min	98 h 11 min	73 h 33 min	84 h 9 min	40 h 1 min	Accompanied by severe intellectual, language, motor development disorders	40 min

ADEM, acute disseminated encephalomyelitis; Survival time, Time of presentation to death

levels were decreased in 62.5% of patients. All patients had elevated procalcitonin, and 50% had elevated C-reactive protein. Moreover, all patients exhibited elevated lactic acid ($n = 8/8$), interleukin-6 ($n = 7/7$), D-dimer ($n = 8/8$) and myoglobin ($n = 3/3$). Most patients had high creatine kinase-MB ($n = 7/8$, 87.5%), cardiac troponin I ($n = 6/7$, 85.7%), creatine kinase ($n = 5/7$, 71.4%), lactate dehydrogenase ($n = 6/7$, 85.7%), alanine aminotransferase ($n = 7/8$, 87.5%), aspartate aminotransferase ($n = 7/8$, 87.5%), and immunoglobulin E ($n = 3/4$, 75%) levels. We observed a decrease in albumin levels in seven of eight patients (87.5%). The plasma ammonia levels of most children were within the normal range ($n = 5/6$, 83.33%) (Table 2).

Chest imaging showed that seven patients were complicated with pneumonia. However, the imaging also showed that it was not typical viral pneumonia; rather, it was considered to be hypostatic pneumonia caused by convulsive coma. Moreover, one child had bronchitis. Six patients underwent cardiac ultrasound, two of whom had decreased left heart function (ejection fraction < 40%). Two patients were complicated with myocarditis, and one child had arrhythmia.

Since the vital signs of case 9 had disappeared upon admission, there was no brain imaging and lumbar puncture examination.Five patients underwent lumbar puncture but were not tested for COVID-19 and had normal cerebrospinal fluid white blood cell counts. Four patients exhibited CSF proteinnacell separation and increased CSF protein levels were observed in 80% of children.The lactate dehydrogenase level in the CSF of three patients was increased by 60%. The protein and lactate dehydrogenase levels in the CSF of the surviving child were normal (Table 3).

Craniocerebral imaging examination was performed in 7 patients. Craniocerebral CT examination was completed in case 1,3,5, and 6, and craniocerebral magnetic resonance examination was completed in case 2,4, and 8. Case 1 and 5 were no obvious abnormalities in craniocerebral CT examination. One child (case 6) had a bilateral thalamic lesion on cranial CT on the second day after illness, along with swelling of the midbrain and pons (Fig. 1). One child (case 8) showed abnormal MRI signals in the corpus callosum, and the encephalogram showed a small amount of multifocal discharge during waking hours and a slow background rhythm; sleep was highly arrhythmic. Cranial MRI of one child (case 2) showed multiple abnormal signals in the brain, considered indicative of infectious lesions, and the encephalogram showed persistent and widespread low voltage. Another child (case 4) showed abnormal signals in the bilateral basal ganglia, thalamus, corpus callosum, pons, and multiple areas under the cerebral cortex, and encephalogram showed persistent and widespread low voltage. Finally, diffuse cerebral edema was seen in one child (case 3).

Treatment regimen and prognosis

One child who presented to the emergency department with respiratory and cardiac arrest died despite treatment with active chest compression, positive pressure ventilation, and vasoactive drugs. The remaining eight patients were admitted to the PICU and received comprehensive anti-infection, intracranial pressure reduction, and mechanical ventilation treatments. In the PICU, all eight of these patients were given glucocorticoids (pulse methylprednisolone, 20 mg/kg/day [maximum = 1 g/day]) and intravenous human immunoglobulin (2 g/kg [maximum dose = 80 g). To address inflammatory factors, two patients underwent plasmapheresis and three underwent hemodialysis. Because of abnormal coagulation function, plasma transfusion was given to seven patients

Table 2 Abnormal laboratory data categorized from the normal range

Case No.	1	2	3	4	5	6	7	8	9	Normal range	available laboratory measurement, *n*	abnormal laboratory value, *n* (%)
White blood cell, $\times 10^9$/ L	12.63	21.82	5.63	3.19	7.19	9.57	9.68	3.28	-	1∼<2years,5.1∼14.1 2∼<6years,4.4∼11.9 6∼<13years,4.3∼11.3	8	Elevated,3(37.5)
Neutrophil count, $\times 10^9$/L	11.4	20.16	5.09	2.17	6.4	9.19	8.34	2.27	-	1∼<2years,0.8∼5.8 2∼<6years,1.2∼7.0 6∼<13years,1.6∼7.8	8	Elevated,4(50)
Neutrophil count, %	90.3	84.4	90.5	67.9	88.9	96	86.1	69.2	-	1∼<2years,13∼54 2∼<6years,22∼65 6∼<13years,31∼70	8	Elevated,8(100)
Lymphocyte count, $\times 10^9$/L	0.73	0.72	0.26	0.73	0.66	0.35	1.16	0.74	-	1∼<2years,2.7∼9.1 2∼<6years,1.8∼6.3 6∼<13years,1.5∼4.6	8	Low,8(100)
Lymphocyte count, %	5.7	3.3	4.6	22.9	9.2	3.7	12	8.2	-	1∼<2years,33∼77 2∼<6years,23∼69 6∼<13years,23∼59	8	Low,8(100)
Neutrophil-to-lymphocyte ratio, %	15.62	28	19.58	2.978	9.70	26.26	7.19	3.07	-	≤5	8	Elevated,6(75)
Platelet count,$\times 10^9$/ L	253	90	139	210	29	13	47	42	-	1∼<2years,190∼524 2∼<6years,188∼472 6∼<12years,167∼453	8	Low,5(62.5)
Hemoglobin, g/L	132	90	147	112	102	76	110	73	-	1∼<2years,107∼141 2∼<6years,112∼149 6∼<13years,118∼156	8	Low,5(62.5)
C-reactive protein level, U/L	80.11	5.75	178.6	1.79	8.18	3.3	1.9	67.49	-	0–6	8	Elevated,4(50.0)
Procalcitonin, ng/ml	80.11	5.75	178.6	1.79	8.18	3.3	1.9	67.49	-	0-0.05	7	Elevated,7(100)
D-dimer, mg/L	10.06	35.33	6.9	-	83.12	168.94	100.94	82.2	-	0-0.5	8	Elevated,8(100)
Creatine kinase-MB, ng/ml	70.2	6.93	38.8	5.9	36.28	66	19.8	21.14	-	0–5	8	Elevated,7(87.5)
Cardiac troponin I, pg/ml	4.90	0.00	10.55	-	4.59	5.86	2.79	0.13	-	0-0.175	7	Elevated,6(85.7)
Myoglobin, μg/L	-	-	1473.7	-	849.4	>4007	-	-	-	1.5–70	3	Elevated,3(100)
Creatine kinase, U/L	-	569	2422	201	2896	6820	690	287	-	50–310	7	Elevated,5(71.4)
Lactate dehydrogenase, U/L	-	1175	506	249	1077	1845	852	587	-	120–250	7	Elevated,6(85.7)
Creatinine, μmol/L	66.8	45.4	218.2	22.6	208.1	145	98	31.2	-	28days∼<2years,13∼33 2∼<6years,19∼44 6∼<13years,27∼66	8	Elevated,5(62.5)

Table 2 (continued)

Case No.	1	2	3	4	5	6	7	8	9	Normal range	available laboratory measurement, *n*	abnormal laboratory value, *n* (%)
Blood urea nitrogen, mmol/L	4.39	3.9	8.5	2.7	5.9	3.2	12.8	2.2	-	1∼<2years,2.3∼6.7 2∼18years, 2.7∼7.0(male) 2.5∼6.5(female)	8	Elevated,2(25)
Alanine aminotransferase, U/L	131.7	356.4	55.4	8.4	10,476	10,000	62.5	1078	-	1∼<2years,8∼42 2∼<13years,7∼30	8	Elevated,7(87.5)
Aspartate aminotransferase, U/L	351	130	134	40	20,736	20,248	229	352	-	1∼<2years,11∼47 2∼<13years,8∼30	8	Elevated,7(87.5)
Albumin, g/L	34.4	28.7	40.2	35.2	28.3	37.2	46.7	34.6	-	6months∼<13years, 39∼54	8	Low,7(87.5)
NT-pro B-type -triuretic peptide, pg/ml	179	332	65	-	39	4	22	278	-	0-100	7	Elevated,3(42.9)
Lactic acid, mmol/L	4.1	8.7	3.3	3.2	12.1	14.6	12.2	2.2	-	0.5–1.8	8	Elevated, 8(100)
Ferritin, ng/mL	1072.28	90.36	220.16	-	-	-	-	-	-	Male,21.81–274.66 Famale,4.63–204.00	3	Elevated ,1(33.3)
Plasma ammonia, umol/L	-	<8.7	13.6	-	9.1	49.9	13.4	19.5	-	9–33	6	Elevated,1(16.7)
Interleukin-6, pg/ml	41.3	18.8	140	-	208	>1000	>1000	20.2	-	0-3.4	7	Elevated, 7(100)
Immunoglobulin E, IU/mL	795	55.2	558	-	-	8.2	-	-	-	1 ~ 5years,< 60 10 ~ 15years,< 200	4	Elevated ,3(75)
Immunoglobulin A, g/L	1.88	0.16	2.58	-	-	1.56	<0.27	0.38	-	0.7-4	6	Low,3(50)
Immunoglobulin M, g/L	1.02	0.75	0.76	-	-	0.67	0.67	1.03	-	0.4–2.3	6	Low,0(0)
Immunoglobulin G, g/L	10.5	3.79	13.8	-	-	6.77	4.38	4.16	-	7–16	6	Low,2(33.3)

Table 3 The CSF and neuroimaging results of children

No.	CSF protein, g/L	CSF white blood cells, $\times 10^6$/ L	CSF Lactate dehydrogenase, U/L	CT of the brain	MRI of the brain	Encephlogram	Diagnosis of central nerve system damage
1	1.84	10	657	plain scanning, no obvious abnormalities	-	-	Necrotic encephalopathy, severe encephalitis
2	1.52	3	157	-	multiple abnormal signals in the brain, infectious disease likely, acute disseminated encephalomyelitis possible	Broad persistent low voltage pattern	severe encephalitis
3	-	-	-	1. Subarachnoid hemorrhage, diffuse cerebral edema, 2. Bilateral globus pallidus, caudate nucleus head symmetrical high-density shadow	-	-	Necrotic encephalopathy, severe encephalitis
4	2.18	12	37	-	multiple symmetric abnormal signals in bilateral basal ganglia-thalamus, corpus callosum, pons, and cerebral cortex	Broad persistent low voltage pattern	Necrotic encephalopathy, severe encephalitis
5	-	-	-	Plain scanning, no obvious abnormalities	-	-	severe encephalitis
6	-	-	-	1. Bilateral thalamic-midbrain and pontine swelling, ring cistern and fourth ventricle unclear 2. Minor subarachnoid hemorrhage.	-	-	Severe encephalitis, subarachnoid hemorrhage
7	6.25	2	188	-	-	-	severe encephalitis
8	0.27	6	28	-	Abnormal signal foci on the left side of the corpus callosum pressure	A small amount of multi-focal discharge in waking period, slow background rhythm; Sleep is highly arrhythmic	severe encephalitis
9	-	-	-	-	-	-	severe encephalitis

CSF protein, Normal range 0–0.4 g/L.CSF white blood cells, Normal range 0–15 $\times 10^6$/ L.CSF Lactate dehydrogenase, Normal range 3-40U/L

and cryoprecipitate was given to three patients. Because of varying degrees of anemia, three patients underwent "suspended" red blood cell infusion to enhance blood oxygen carrying capacity. Because of severe shock or multiorgan failure, seven patients died 12 h to 5 days after onset, and no cases were autopsied. We followed one child (case 8) receiving antiepileptic and rehabilitation therapy for 6 months and noted frequent nodding spasms after startle and infection. This patient had severe motor and neurodevelopmental delay; now aged 2 years and 7 months, the child is still unable to sit or stand.(Table 1).

Discussion

Of the nine patients, seven were male (77.78%). Five children were aged ≥ 10 years, and the others were 1–2 years old. All children had fever, eight had convulsions, seven had progressed to multiple organ failure, and all suffered varying degrees of coma. The cranial imaging results of five children were abnormal. One child had lost his vital signs when admitted to hospital, and the remaining eight received hormonal shock, human immunoglobulin transfusion, antinainfection, cranial pressure reduction, and tracheal intubation, among others, during hospitalization. Ultimately, eight children died, and the remaining child has serious neurological sequelae and is undergoing rehabilitation.

The COVID-19 virus has undergone several mutations since its discovery in 2020. The Omicron variant was first identified in South Africa in November 2021 [9]. This variant spreads more rapidly and has a greater ability to evade immunity than other variants [10], and it has been the dominant strain globally since February 2022 [11]. Approximately 1 week after the adjustment of epidemic prevention policies, an Omicron infection broke out in mid-December 2022 in eastern China, which reached a peak in around 2 weeks and declined rapidly

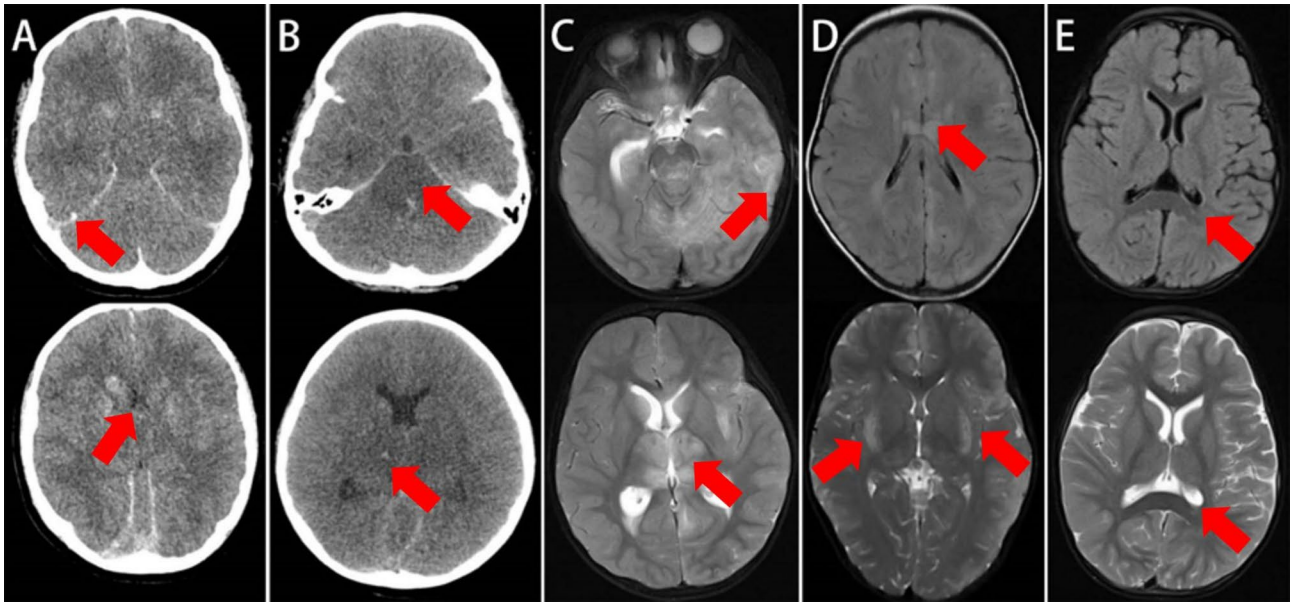

Fig. 1 **A** (case 3), cranial CT, Subarachnoid hemorrhage, diffuse cerebral edema; **B** (case 6),cranial CT, Bilateral thalamic-midbrain and pontine swelling, subarachnoid hemorrhage; **C** (case 2), cranial MRI, multiple abnormal signals in the brain; **D** (case 4),cranial MRI, T2-FLAIR hyperintense signal, T2WI hyperintense signal; **E** (case 8),cranial MRI, T2-FLAIR hyperintense signal

3 weeks thereafter. During this period, monitoring by the local Center for Disease Control and Prevention showed that the circulating strains were BA.5.2 and BF.7; no other strains were found. The local Omicron variant spread rapidly, with a short incubation period (typically 2–4 days). The main symptoms of infection in pediatric patients include fever of varying severity (typically moderate-to-high fever) and febrile seizures. However, the prognosis is good. In the majority of patients, the fever lasted 1–3 days and rarely persisted for > 5 days. A small number of patients suffered coughs, sore throats, headaches, and fatigue, and pneumonia developed in a very small number of cases. Within 43 days after the lifting of lockdown, a total of 9,500 children presented to the center with fever. Among these children, we identified nine with severe CNS injury caused by COVID-19 (morbidity rate = 0.09%). Many pediatric cases of multisystem inflammatory response syndrome induced by COVID-19 have been reported in Europe, the United States, and other parts of China [12, 13]. Moreover, the locally endemic Omicron variant caused more severe neurological lesions in pediatric patients than severe lower respiratory pathologies.

At present, our understanding of CNS injury caused by COVID-19 is insufficient, and no clear conclusion on the pathogenesis has been drawn. Following infection, COVID-19 enters the CNS through a variety of pathways, such as the blood circulation, sieve plates, and synaptic pathways [14–16]. Viruses can cause nerve damage by directly invading the nervous system, leading to tissue hypoxia, inflammatory mediators producing cytokine storms [17, 18], anosmia, taste disorders, viral encephalitis [19, 20], demyelinating lesions [21], toxic encephalopathy [22], and necrotizing encephalopathy, etcetera. At the beginning of the pandemic in 2020, necrotizing encephalopathy in adults caused by COVID-19 infection was reported both in China and elsewhere [23]. In May 2021, Lazarte-Rantes et al. reported the first pediatric cases of acute necrotizing encephalopathy associated with COVID-19 [24]. The patients in the above reports all exhibited rapid progression, poor prognosis, and a requirement for mechanical ventilation during treatment. The first reported pediatric case with necrotizing encephalopathy was discharged with severe neurological sequelae [24].

This study reported cases of severe CNS injury in children infected with COVID-19 who presented to our center during the pandemic. We analyzed the incidence, clinical manifestations, imaging examination and laboratory results, and prognoses. All patients had severe CNS injury, and eight pediatric patients developed fever and convulsions. All patients experienced varying degrees of coma, ranging from fever to coma between 2 h and 3 days in duration. Three children were diagnosed with necrotizing encephalopathy. CSF and brain imaging examinations were not performed in two patients because of rapid disease progression, but necrotizing encephalopathy was highly suspected clinically. In this study, there were more male than female patients, which is inconsistent with previous studies and may be related to the small sample size [25]. Most patients exhibited inflammatory cytokine storm, ultrahigh fever, cranial imaging

abnormalities, and symmetric multifocal brain damage. We also found that most of the children had abnormal liver, heart, coagulation, and hematopoietic function. This finding is suggestive of multiorgan failure. Their disease progressed rapidly, which is apt to give rise to multiple organ dysfunction and a poor prognosis, especially in older children. Even if they survive, such patients are likely to suffer serious neurological sequelae.

Importantly, of the nine children in this study, five underwent a complete CSF examination, and four had significantly higher CSF protein levels than normal; all of the latter patients died. The CSF protein levels of the surviving child were normal. In a previous report, all seven children with COVID-19 complicated with neurological manifestations who died had elevated CSF protein levels [26]. In another study, the CSF protein levels of five children who died of COVID-19 complicated with necrotizing encephalopathy were higher than those of the surviving children [25]. Finally, the CSF protein levels of surviving children with severe encephalopathy were found to be normal [27]. We speculate that decreased CSF protein levels may be a protective factor for severe neurological impairment or death in children with necrotizing encephalopathy caused by COVID-19.

Limitations

This study had two limitations. First, the sample size was small. Second, this retrospective study enrolled hospitalized children from a single center. Multicenter studies with larger sample sizes are needed.

Conclusions

COVID-19 can cause severe damage to the CNS in pediatric patients. A low level of CSF protein may be a protective factor for death in children with severe neurological damage caused by COVID-19. In view of the high mortality and disability rates of COVID-19-related severe CNS injury, the clinical symptoms of pediatric patients need to be studied in greater depth. It is hoped that this article will serve as a reference for the diagnosis, treatment and management of severe CNS injury associated with COVID-19 in children.

Acknowledgements

We would like to thank all the pediatric staff of the Affiliated Hospital of Jining Medical University for their support and help.

Author contributions

PPZ, NL contributed to primary manuscript writing and editing.MYX has made outstanding contributions to the preparation, planning and revision of it, and put forward some valuable ideas. YGB was responsible for the collection and interpretation of data. XYR was responsible for the quality control and supervision of medical records.All authors contributed to the paper and approved the submitted version.All authors contributed to study conceptualization and design.

Funding

This work was supported by the Affiliated Hospital of Jining Medical University. (grant number 2020-BS-010,2022-yxyc-002,JYFY363231).

Data availability

No datasets were generated or analysed during the current study.

Declarations

Ethics approval and consent to participate

The study was conducted in accordance with the Declaration of Helsinki (as revised in 2013). This study was approved by the Ethics Committee of Affiliated Hospital of Jining Medical University(Ethical number:2022C253). All methods were carried out in accordance with relevant guidelines and regulations.Confirm that the informed consent of all subjects' legal guardians has been obtained for this study.

Consent for publication

Consent for publication Written informed consent for publication of their clinical details and/or clinical images was obtained from the parent of the patient.

Competing interests

The authors declare no competing interests.

Received: 27 November 2023 / Accepted: 16 January 2025
Published online: 27 January 2025

References

1. Li YC, Bai WZ, Hashikawa T. The neuroinvasive potential of SARS-CoV2 may play a role in the respiratory failure of COVID-19 patients. J Med Virol. 2020;92(6):552–5. https://doi.org/10.1002/jmv.25728.
2. Huang C. Wang Yeming,Li Xingwang Clinical features of patients infected with 2019 novel coronavirus in Wuhan, China. Lancet, 395(10223), 497–506. https://doi.org/10.1016/S0140-6736(20)30183-5
3. Siow I, Lee KS, Zhang JJY, et al. Encephalitis as a neurological complication of COVID-19: a systematic review and meta-analysis of incidence, outcomes, and predictors. Eur J Neurol. 2021;28:3491–502. https://doi.org/10.1111/ene.14913.
4. Shimohata T, Neuro, -COVID-19. Clin Exp Neuroimmunol. 2022;13(1):17–23. https://doi.org/10.1111/cen3.12676.
5. Panda PK, Sharawat IK, Panda P, et al. Neurological complications of SARS-CoV -2 infection in children: a systematic review and meta-analysis. J Trop Pediatr. 2021;67(3). https://doi.org/10.1093/tropej/fmaa070.
6. Valderas C, Méndez G, Echeverría A, et al. COVID-19 and neurologic manifestations: a synthesis from the child neurologist's corner. World J Pediatr. 2022;18(6):373–82. https://doi.org/10.1007/s12519-022-00550-4.
7. Umapathi T, Quek WMJ, Yen JM et al. Encephalopathy in COVID-19 patients; viral, parainfectious, or both? eNeurologicalsci.2020;21:100275.https://doi.org/10.1016/j.ensci. 2020.100275.
8. Jia, Jianping. Chen Shengdi. Neurology. People's Medical Publishing House; 2018.
9. Callaway E. Heavily mutated Omicron variant puts scientists on alert[J]. Nature. 2021;600(7887):21. https://doi.org/10.1038/d41586-021-03552-w.
10. Viana R, Moyo S, Amoako DG, et al. Rapid epidemic expansion of the SARS-CoV-2 Omicron variant in southern Africa. Nature. 2022;603(7902):679–86. https://doi.org/10.1038/s41586-022-04411-y.
11. Jiao FY, Ma L. Strengthening the prevention and treatment of Omicron infection in children. Chin J Contemp Pediatr 2022,24(4):345–910.7499/j.issn.1008-8830.2201001
12. Zhi GF. Yan MB,Yong HY,et al.Severe acute respiratory syndrome coronavirus 2-induced multisystem inflammatory syndrome in children. Pediatr Investig. 2020;4(4):257–62. https://doi.org/10.1002/ped4.12225.
13. Waseem M, MS M, Shariff MA, et al. Multisystem inflammatory syndrome in children. J Emerg Med. 2022;62:28–37. https://doi.org/10.1016/j.jemer-med.2021.07.070.
14. BaigAM. KhaleeqA,AliU,evidence of the COVID-19 virus targeting the cns: tissue distribution, host-virus interaction,and proposed neurotropic mechanisms.ACS Chem Neurosci,2020,11(7):995–810.1021/acschemneuro.0c00122

15. BaigAM. Neurological manifestations in COVID-19 caused by SARS-CoV-2. CNS neurosci Ther,2020,26(5):499–501.https://doi.org/10.1111/cns.13372
16. LiYC,BaiWZ,HashikawaT. The neuroinvasive potential of SARS-CoV2 may play a role in the respiratory failure of COVID-19 patients. J Med Virol 2020,92(6): 552–510.1002/jmv.25728
17. ChenC. ZhangXR,JuZY,advances in the research of mechanism and related immunotherapy on the cytokine storm induced by coronavirus disease 2019. Chin J Burns 2020,36(6):471–510.3760/cma.j.cn501120-20200224-00088
18. MehtaP,McAuleyDF. BrownM,etal.COVID-19:consider cytokine storm syndromes and immunosuppression.Lancet,2020,395(10229):1033–4.https://doi.org/10.1016/S01 40-6736(20)30628-0.
19. MoriguchiT,HariiN. GotoJ,a first case of meningitis/encephalitis associat ed with SARS-Coronavirus-2. Int J Infect Dis 2020,94:55–810.1016/j.ijid. 2020.03.062
20. YeM,RenY. LvT.Encephalitis as a clinical manifestation of COVID-19.Brain Behav Immun,2020,88:945–610.1016/j.bbi.2020.04.017
21. SedaghatZ,KarimiN. Guillain Barre syndrome associated with COVID-19 infection:a case report. J Clin Neurosci. 2020;76:233–5. https://doi.org/10.1016/j.jocn.2020. 04.062.
22. GuoYR,CaoQD,HongZS. The origin, transmission and clinical therapies on coronavirus disease 2019 (COVID-19) outbreak-an update on the status. Mil Med Res 2020,7(1):11.https://doi.org/10.1186/s40779-020-00240-0
23. Dixon L, VarleyJ,Gontsarova A et al. COVID-19-related acute necrotizing encephalopathy with brain stem involvement in a patient with aplastic anemia.Nuro l Neuroimmunol Neuroinflamm,2020,7(5):e789.https://doi.org/10.1212/NXI.0000000000000789
24. Lazarte-Rantes C, Guevara-Castañón J, Romero L, Guillén-Pinto D. Acute Necrotizing Encephalopathy Associated with SARS-CoV-2 exposure in a Pediatric patient. Cureus. 2021;13(5):e15018. https://doi.org/10.7759/cureus.15018.
25. Lin X et al. Wang Ying,Li Xiaoying. Acute necrotizing encephalopathy in children with COVID-19: a retrospective study of 12 cases.Front Neurol, 2023, 14: 1184864.https://doi.org/10.3389/fneur.2023.1184864
26. Tandon Medha,Kataria Saurabh,Patel, Jenil, et al. A comprehensive systematic review of CSF analysis that defines neurological manifestations of COVID-19. Int J Infect Dis. 2021;104:390–7. https://doi.org/10.1016/j.ijid.2021.01.002.
27. Zhang Tao WANG, Li-jie XU, Wei et al. Clinical features of three children with severe COVID-19 encephalopathy and literature review[J].Chinese Pediatric Emergency Medicine,2023,30(3):E001.https://doi.org/10.3760/cma.j.issn.1673-4912.2023

Publisher's note

Springer Nature remains neutral with regard to jurisdictional claims in published maps and institutional affiliations.